

ALK+ Inflammatory Myofibroblastic Tumor of the Tongue in a Neonate Treated With Crizotinib

Maraya M. Baumanis, MD^{1*}; Pamela Nicklaus, MD²; Melissa Gener, MD³

¹ Department of Otolaryngology-Head & Neck Surgery, University of Kansas School of Medicine, Kansas City, Kansas, USA

² Division of Pediatric Otolaryngology-Head & Neck Surgery, Children's Mercy Hospital, Kansas City, Missouri, USA

³ Division of Pathology, Children's Mercy Hospital, Kansas City, Missouri, USA



ABSTRACT

Inflammatory myofibroblastic tumor (IMT) is a rare, mesenchymal low-grade neoplasm characterized by benign histology but has the potential of showing aggressive clinical behavior with local invasiveness and recurrence. It primarily occurs in children and young adults in the lung and abdominopelvic regions, but there are reports of oral cavity IMTs. In this report, the authors present a case of a neonate born with an enlarging tongue mass whose biopsy revealed IMT with anaplastic lymphoma kinase (ALK) positivity. Treatment included tumor debulking and an ALK inhibitor, crizotinib, which resulted in complete remission. To our knowledge, this is the only reported case of oral cavity IMT with ALK positivity in a neonate.

INTRODUCTION

Inflammatory myofibroblastic tumor (IMT) is a rare, mesenchymal neoplasm primarily occurring in the lung and abdominopelvic regions in children and young adults with a prevalence ranging from 0.04-0.7% [1-3]. IMT presents as a painless, enlarging mass and may show invasiveness and local recurrence but is rarely metastatic [4].

Histologic characteristics include a mixture of inflammatory and myofibroblastic spindle cells with hypocellular fibrous patterns that can be well-circumscribed to ill-defined on imaging [1,3]. Surgical intervention have been mostly noted as the mainstay treatment for IMTs, though chemotherapy agents and anti-inflammatory therapies such as steroidal and non-steroidal anti-inflammatory drugs have been reported, as well [5].

To date, there are published cases of IMT involving the head and neck, including the oral cavity, but to our knowledge, there are no reported studies of inflammatory myofibroblastic tumor with anaplastic lymphoma kinase (ALK) positivity of the tongue in a neonate [2,4,6-16].

CASE REPORT

A 0-day-old neonate, born without complication at 41 weeks, presented as a transfer from an outside facility to Children's Mercy Hospital (CMH) in Kansas City, Missouri for further evaluation and management of a large, bleeding tongue mass. Of note, there was reported comprehensive antenatal care without complication or detection of the tongue mass on three prenatal ultrasounds. At birth, the tongue mass was noted. The patient did not have significant airway obstruction with APGARs 8 and 9 at one and five minutes of life, respectively. On physical exam, there was a large, firm, oozing tongue mass with transition from normal appearing tongue mucosa to necrotic and atypical tongue mucosa roughly halfway posterior on the lingual surface (Figure 1). The patient's airway was widely patent on flexible laryngoscopic exam, and she was saturating well on room air.

The patient then underwent transnasal intubation in the operating room and magnetic resonance imaging (MRI). MRI face with and without contrast showed a large mass that filled and distorted the normal anatomy of the oral cavity and floor of mouth with extent inferiorly and laterally to the level of the mandible without bony extension and superiorly to the level of the hard

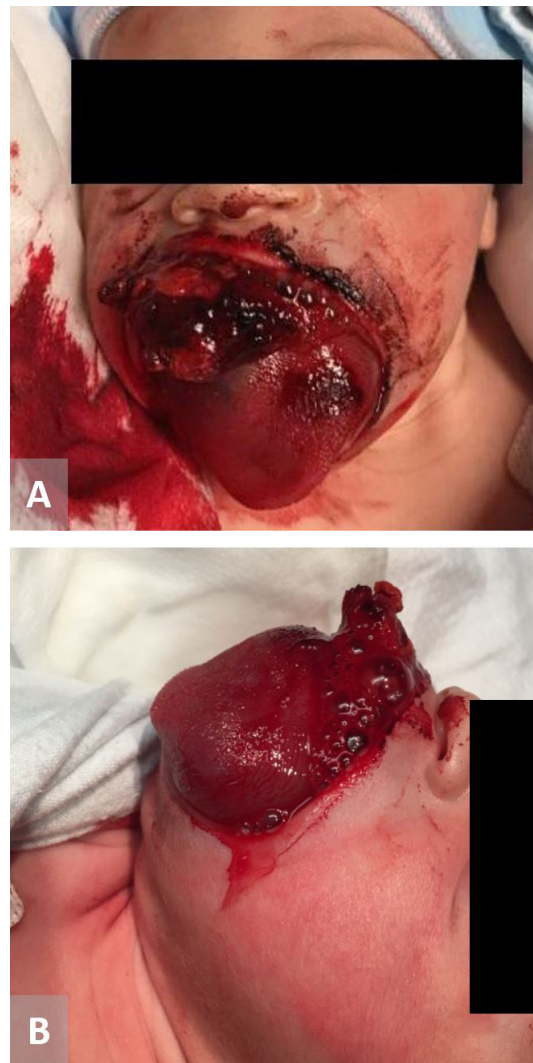


Figure 1. 24-hour neonate with a several centimeter tongue mass with hemorrhage. (A) Frontal view. (B) Lateral view.

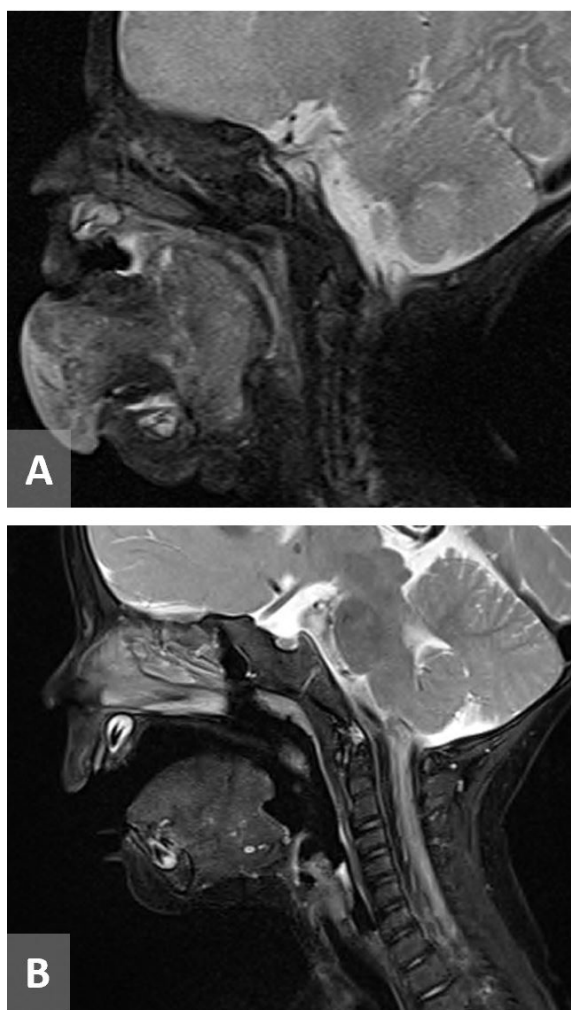


Figure 2. (A) MRI T2 sequence showing a large tongue mass that is heterogeneously hyperintense without vascular flow voids measuring 3.4 x 5.5 x 3.1 cm. (B) MRI T2 sequence 5 months post-treatment. MRI, magnetic resonance imaging.

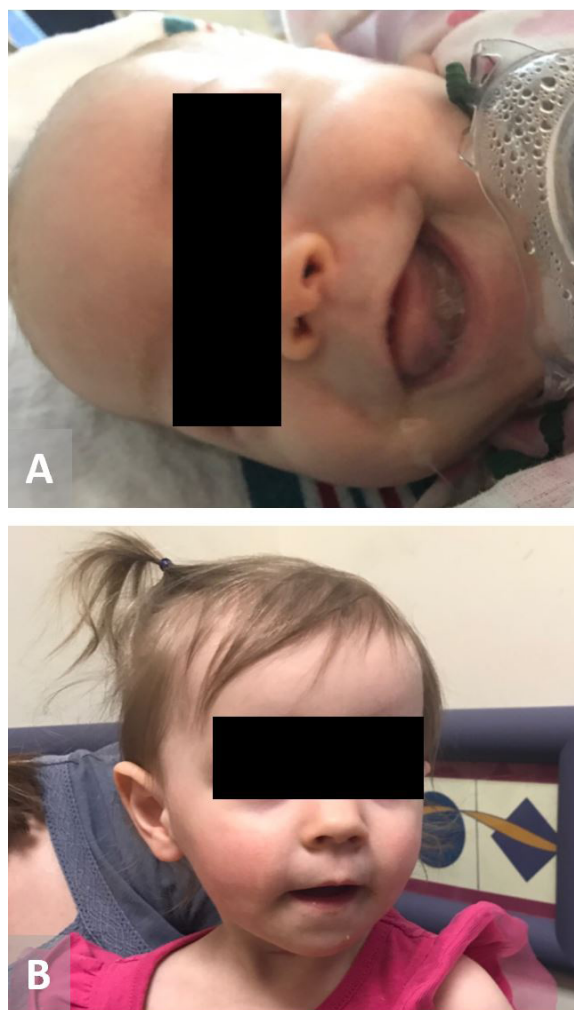

Figure 3. Shrinkage of tongue mass after initiation of chemotherapeutic agent, crizotinib. (A) At 2 months of age. (B) At 18 months of age.

palate and posteroinferiorly to the vallecula, measuring 3.4 x 5.5 x 3.1 cm. The mass was isointense to soft tissue on T1 and heterogeneously hyperintense on T2 with absence of vascular flow voids (Figure 2). MRI brain was noted to be normal.

Biopsy of the tongue mass, tracheotomy, and gastrostomy tube placement occurred. Pathology, which was analyzed by CMH and an outside facility, was consistent with a congenital inflammatory myofibroblastic tumor with ALK, S100-protein, smooth muscle actin (SMA), desmin, and p53 positivity.

Traditional therapy would be complete resection, but in this patient would require subtotal glossectomy. Due to the high morbidity with this procedure, we received compassionate approval for targeted therapy with an ALK inhibitor, crizotinib. Prior to initiation of therapy, due to the necrotic nature of the tumor, debulking was performed. Despite initial growth of the tumor, after twelve months of receiving crizotinib, there was good response with noticeable shrinkage of the tumor (Figure 3A). The patient did have prolongation of her QTc interval, though a normal baseline echocardiogram, which can be a side effect of crizotinib. She underwent serial electrocardiograms (EKGs) during treatment to monitor her QTc interval, which normalized after cessation of crizotinib. The patient was last seen at 18 months old, off of therapy for eight months without signs or symptoms of recurrence with no detectable tumor by MRI imaging (Figure 2B). She has been decannulated with removal of her gastrostomy tube without difficulties talking, swallowing, or breathing (Figure 3B).

DISCUSSION

Overview

Inflammatory myofibroblastic tumor is an overall rare, mesenchymal neoplasm that occurs primarily in the lung and abdominopelvic regions, with only 14-18% of the extrapulmonary IMTs occurring in the head and neck region [5]. Of that small subset of head and neck occurrences, the orbits and upper airways are most common [5]. Our study adds to the literature in that it is a tongue IMT, positive for ALK, in a neonate.

Pathological, Histological, and Imaging Features

Extrapulmonary cases of inflammatory myofibroblastic tumor show a combination of spindled fibroblastic and myofibroblastic cells with inflammatory infiltrate of lymphocytes, eosinophils and plasma cells [17]. The pathology in our patient showed relatively monotonous sheets of cells with ovoid to spindle-shaped nuclei, indistinct pale-gray cytoplasm with a delicate slightly vacuolated chromatin pattern (Figure 4). Mitotic figures and foci of necrosis visible. Other features are prominent hemangiopericytomatous vasculature with lymphocytic infiltrate and focal collections of osteoclastic giant cells. Fluorescence in situ hybridization (FISH) was positive for ALK in our patient. Positivity for the ALK gene has been reported in approximately 50% of IMTs [1,18]. The diagnosis of IMT requires histo-

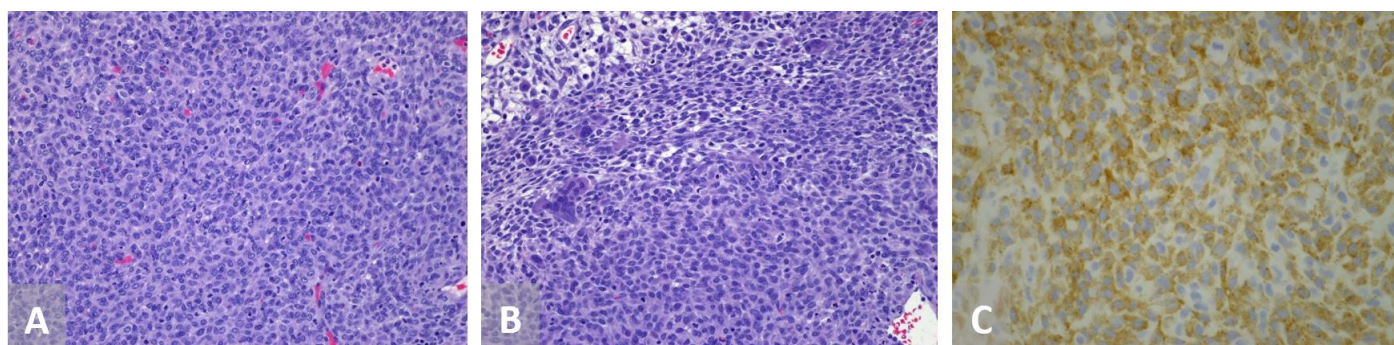


Figure 4. (A) Pathology showing monotonous sheets of cells with ovoid to spindle-shaped nuclei, indistinct pale-gray cytoplasm with a delicate slightly vacuolated chromatin pattern, 200 x. (B) Other features include prominent hemangiopericytomatous vasculature with lymphocytic infiltrate and focal collections of osteoclastic giant cells, 200x. (C) Cells stained for anaplastic lymphoma kinase positivity, 400x.

logical and immunohistochemical staining to confirm diagnosis [8]. In this case, ALK, S-100 protein, SMA, desmin and p53 was positive. In a study observing immunohistochemical aspects of IMT, it showed vimentin was present in 100% of the cases (30/30) then in descending order SMA at 70% (21/30), desmin and ALK at 27% (8/30), and cytokeratin (CK) at 13% (4/30) [17]. Another study confirmed that most commonly SMA and vimentin are found to be positive to diagnose IMT [19].

Imaging features are variable depending where they are found in the body. Commonly, one will see an ill-defined soft tissue mass with heterogeneous enhancement with or without invasive features on computed tomographic (CT) or MRI [19].

Treatment

Traditionally, since IMT is noted to be an aggressive and localized disease, treatment options for head and neck IMT have been reported to be managed with complete surgical resection [1,20]. Though, there are cases in which ALK gene positivity can be treated successfully with medical management, such as crizotinib. Crizotinib, a first-generation ALK inhibitor, has been shown to have good response rates in IMT with ALK positivity. Other therapies such as chemotherapy agents and radiotherapy have been described for unresectable tumors [21]. Adjuvant therapies such as steroidal and non-steroidal anti-inflammatory agents have been shown to be beneficial in metastatic disease [1]. In our case, a subtotal to complete glossectomy would have been the surgical treatment. This option would have been extremely morbid in a neonate, so further options were explored including a combination of a surgical debulking of the tongue mass with medical management administration of crizotinib. Crizotinib has possible side effects including visual disorders, gastrointestinal effects, hepatotoxicity, pneumonitis, and cardiac effects such as QTc interval prolongation and bradycardia [22].

Outcomes

Outcomes seem to be substantial in surgical interventions, whether complete or partial resections, for treatment of IMTs [5]. Further, when observing the use of an ALK inhibitor agent in ALK positive IMTs, Thielen et al. reported achievement of partial to complete remission in 40% (12/30) patients with use of crizotinib [23]. Another study observed metastatic or inoperable ALK+ IMT reported the overall response rate for patients with IMT was 86% (N=14) with a partial response seen in 36% (5/14) [24]. The recurrence rate has been reported to be low with a 10-year survival rate at approximately 80% [1]. Our unique case showed complete clinical and radiological remission without recurrence at 8 months post-treatment with use of crizotinib.

CONCLUSION

Inflammatory myofibroblastic tumor is a low-grade malignancy that rarely occurs in the head and neck. To date, there are no reportable cases of IMT with ALK positivity occurring in the tongue in a neonate. Though, surgical resection has been the mainstay of treatment for IMTs, if positive for ALK, crizotinib may be considered. This study shows complete remission in an enlarging tongue mass in a neonate treated with crizotinib with no signs of recurrence at eight months follow-up. Therefore, it is important for clinicians to consider other treatment options for IMT in select patient populations.

ARTICLE INFORMATION

***Correspondence:** Maraya M. Baumanis, MD. Department of Otolaryngology-Head & Neck Surgery, The University of Kansas Medical Center, Otolaryngology, 3901 Rainbow Blvd, Kansas City, KS 66160, USA. Email: mbaumanis@kumc.edu

Received: Nov. 25, 2019; **Accepted:** Feb. 03, 2020; **Published:** Feb. 24, 2020

DOI: 10.24983/scitemed.aohns.2020.00124

Ethics Approval and Consent to Participate: The study is in accordance with the ethical standards of the 1964 Helsinki declaration and its later amendments or comparable ethical standards.

Funding: The study did not receive any specific grant from funding agencies in the public, commercial, or not-for-profit sectors.

Conflict of Interest: The authors report no financial or other conflict of interest relevant to this article, which is the intellectual property of the authors.

Copyright © 2020 The Authors. This is an open-access article distributed under the terms of the Creative Commons Attribution 4.0 International License (CC-BY).

ACKNOWLEDGMENTS

Meghan Tracy for support through the manuscript creation and IRB preparation.

REFERENCES

- Panagiotopoulos N, Patrini D, Gvinianidze L, Woo WL, Borg E, Lawrence D. Inflammatory myofibroblastic tumour of the lung: a reactive lesion or a true neoplasm? *J Thorac Dis* 2015;7(5):908-911.
- Shetty SJ, Pereira T, Desai RS. Inflammatory myofibroblastic tumor of the oral cavity: A case report and literature review. *J Cancer Res Ther* 2019;15(3):725-728.
- Surabhi VR, Chua S, Patel RP, Takahashi N, Lalwani N, Prasad SR. Inflammatory Myofibroblastic Tumors: Current Update. *Radiol Clin North Am* 2016;54(3):553-563.
- Kim JS, Hong KH, Kim JS, Song JH. Medical therapy of maxillary sinus inflammatory myofibroblastic tumors. *Am J Otolaryngol* 2016;37(4):376-378.

5. Ma L, Wang K, Liu WK, Zhang YK. Is radical surgery necessary to head and neck inflammatory myofibroblastic tumor (IMT) in children? *Childs Nerv Syst* 2009;25(3):285-291.
6. Sah P, Byatnal AA, Rao L, Narayanaswamy V, Radhakrishnan R. Inflammatory myofibroblastic tumor: a rapidly growing soft tissue mass in the posterior mandible. *Head Neck Pathol* 2013;7(4):393-397.
7. Girardi FM, Fontana CW, Kroef RG, Barra MB, Detanico FO, Herter NT. Laryngeal inflammatory myofibroblastic tumor. *Ear Nose Throat J* 2014;93(12):E10-12.
8. Rahman T, Sharma JD, Krishnatreya M, Kataki AC, Das A. Inflammatory myofibroblastic tumor of the upper alveolus: A rare entity presenting as a jaw swelling. *Ann Maxillofac Surg* 2014;4(2):227-229.
9. Adachi M, Kiho K, Sekine G, et al. Inflammatory Myofibroblastic Tumor Mimicking Apical Periodontitis. *J Endod* 2015;41(12):2079-2082.
10. Naresh N, Malik A, Jeyaraj P, Haranal S. Inflammatory Myofibroblastic Tumor of the Oral Cavity. A Great Mimicker. *N Y State Dent J* 2015;81(4):34-36.
11. Rodgers B, Bhalla V, Zhang D, et al. Bilateral inflammatory myofibroblastic tumor mastoiditis. *Head Neck* 2015;37(11):E142-145.
12. Izadi F, Ghanbari H, Azizi MR, Gasembaglou S, Manteghi MJ, Ghanbari A. Inflammatory Myofibroblastic Tumor of the Larynx: A Case Report. *Iran J Otorhinolaryngol* 2016;28(84):79-82.
13. Tay SY, Balakrishnan A. Laryngeal inflammatory myofibroblastic tumor (IMT): a case report and review of the literature. *J Med Case Rep* 2016;10(1):180.
14. Werner RL, Castle JT. Inflammatory Myofibroblastic Tumor of the Nasal Cavity. *Head Neck Pathol* 2016;10(3):336-339.
15. Silva W, Zavarez LB, Zanferrari FL, et al. Inflammatory Myofibroblastic Tumor: Rare Manifestation in Face. *J Craniofac Surg* 2017;28(8):e751-e752.
16. Alzate Amaya F, Invencio da Costa LF, Martinez Moran A, Alvarez Rodriguez R. Unusual Nasal Insufficiency in an Infant: What's Behind the Nostril? *Ann Otol Rhinol Laryngol* 2019;128(11):1078-1080.
17. Li H, Shen Q, Xia Q, et al. [Clinicopathologic features of extrapulmonary inflammatory myofibroblastic tumor]. *Zhonghua Bing Li Xue Za Zhi* 2014;43(6):370-374.
18. Honda K, Kadowaki S, Kato K, et al. Durable response to the ALK inhibitor alectinib in inflammatory myofibroblastic tumor of the head and neck with a novel SQSTM1-ALK fusion: a case report. *Invest New Drugs* 2019;37(4):791-795.
19. Tan H, Wang B, Xiao H, Lian Y, Gao J. Radiologic and Clinicopathologic Findings of Inflammatory Myofibroblastic Tumor. *J Comput Assist Tomogr* 2017;41(1):90-97.
20. AlKindi MG. A rare case of inflammatory myofibroblastic tumor of the mandible mimicking a malignant tumor. *Saudi Dent J* 2017;29(1):36-40.
21. Zhu Z, Zha Y, Wang W, Wang X, Gao Y, Lv W. Inflammatory Myofibroblastic Tumors in Paranasal Sinus and Nasopharynx: A Clinical Retrospective Study of 13 Cases. *Biomed Res Int* 2018;2018:7928241.
22. Rothenstein JM, Letarte N. Managing treatment-related adverse events associated with Alk inhibitors. *Curr Oncol* 2014;21(1):19-26.
23. Theilen TM, Soerensen J, Bochennek K, et al. Crizotinib in ALK(+) inflammatory myofibroblastic tumors-Current experience and future perspectives. *Pediatr Blood Cancer* 2018;65(4).
24. Mosse YP, Voss SD, Lim MS, et al. Targeting ALK With Crizotinib in Pediatric Anaplastic Large Cell Lymphoma and Inflammatory Myofibroblastic Tumor: A Children's Oncology Group Study. *J Clin Oncol* 2017;35(28):3215-3221.